

Chapter 1

Digestive Fistulas - Introduction

Florin Graur

Mihaela Dragota

Emil Mois

Nadim Al Hajjar

Introduction

A fistula is an abnormal, communication between two organs or between an organ and the exterior, or, rarely, an abscess' cavity. Although rare, a fistula can be created between a vessel and a cavitory organ, therefore producing massive bleeding, which is a surgical emergency. By convention, the system with the highest pressure is named first. A fistula usually has two orifices and a tract.

The fistulas of the digestive tract most commonly appear often after a surgical procedure. Some authors found that 75-85% of the fistulas appear after surgery [1]. And although they are often described as one of the possible complications, special attention must be given to prevent their appearance. The rest of them are considered spontaneous.

Until 1960, fistulas following a surgical procedure on the digestive system had a very high mortality rate, up to 43% [2], but nowadays, thanks to specialized intensive care units, total parenteral nutrition, new antibiotics, new wound care systems, new surgical procedures and endoscopic methods, the mortality rates have reduced drastically. Recent studies describe a variable mortality rate, from 6,5 to 39% [3-7]. Although this complication is sometimes hard to manage from minimally invasive point, many fistulas can be dealt by endoscopy [8], or sometimes a conservative approach can be used [9]. Yet this is a complication that prolongs hospital stay, and many cases need a multidisciplinary approach, increasing the cost of the hospitalization. It is important to mention that the critical days for most post-surgical leakages to arise are between day 5 and day 10 following the procedure [10].

Classification

Despite the fact that there are many fistulas classification, none of them are used entirely. The most common criteria are anatomical, physiological,

etiological features, as well as time of appearance. Besides, depending on the fistula's characteristics, combined with the previous criteria, we can achieve a more detailed description of the fistula.

As said before, depending on the criteria we classify them, fistulas can be assorted into many categories. Therefore, if we choose to distinguish them by the time of their appearance, they can be congenital (such as eso-tracheal fistula - which is a surgical emergency) or acquired (post-abscess, post-procedural).

Another important criteria is the fistula's anatomic components. In this case, a fistula can be internal - when it connects two internal organs, or external - when it connects an internal organ to the skin. Another important aspect of the gastrointestinal fistulas, especially those concerning the small or the large intestine, is whether it is a lateral or a terminal fistula. While a lateral breach assures the continuity of the digestive tract, while some content is passed through the fistula's tract, a terminal one does not, therefore, the terminal one is more severe.

The fistula's tract is another criteria used to tabulate fistulas. Therefore, we can encounter simple fistulas - with a linear tract, and complex fistulas which have an intricate course, with one or more than one branches. We mentioned before that a fistula usually has two orifices and a tract. While this rule applies to most of them, when discussing the complex fistulas, this is not entirely true. A complex fistula can have more than one external orifice or can have a tract that branches out. There is also described blind fistula - the one that has only one opening.

Actually, this criteria can be approached from two ways, depending on the length of the tract, as we can also describe a long (>1 cm) or short (<1 cm) tract, the latter being considered an adverse factor for the spontaneous closure of the fistula [11].

When discussing the fistula's output, we can assort them into low output (the ones that produce less than 200 ml/day, moderate output (200-500 ml/day) and high output (more than 500ml/day) [12]. This classification is very important as high output fistulas are associated with a higher mortality rate [6].

Etiology

Possibly the most important matter when discussing fistulas is the etiology. While the vast majority of the leakages appear after a surgical procedure, there are many factors that must be taken into consideration. The most common surgical procedures that lead to anastomotic leakage are for cancer, inflammatory bowel disease and intestinal obstruction [13, 14]. It is well known that there are some golden rules when performing an anastomosis: a good vascular supply, a tension free anastomosis, a meticulous hemostasis and ensuring there are no hematomas which can lead to infection and leakage. Yet, although all these demands are met, some patients develop this complication.

Timing is very important in surgery. Therefore, the timing between the initial anastomosis and the time the fistula is diagnosed is crucial, as it implies, for its treatment, another major surgery. As said before, most anastomotic leakages appear during the first 5 to 10 days, but there are cases in which this complication can arise up to 30 days postoperatively [15].

Besides the "Golden rules", there are some general risk factors that show an increased anastomotic leak risk:

1. Prolonged surgical time. While some studies suggest that a surgery longer than 2 hours may lead to fistulas, other studies show that such risk appears after more than 4 hours [16].
2. Spilling intestinal content into the operating field it is believed to increase the risk of developing fistulas

3. Hypotension is another risk factor for post procedural fistulas. The main physio-pathological process involves the following sequence: hypoperfusion -> ischemia -> perforation -> fistula
4. While most surgical wounds can be sealed *per primam*, there are some cases in which the closure of the abdominal wall must be closed *per secundam*. In these cases, the exposure of the intestines may lead to fistulas [17].
5. Radiotherapy higher than 50 Gy is considered a risk factor in developing an anastomotic leak. While most postprocedural fistulas appear after an oncological procedure, many of these patients have received, prior to surgery, neoadjuvant radiotherapy, therefore increasing the fibrosis and making the tissue more prone towards leakage. Moreover, Bevacizumab is often administered by the oncological board during radiotherapy, as it increases the tumour's response to radiation. Bevacizumab inhibits VEGF, a growth factor responsible for angiogenesis, therefore increasing the risk for spontaneous perforations and anastomotic leakages [18, 19] (Figure 1).

Treatment

Despite the technological advancement, the modern surgical techniques and the improvement of intensive care unit's management in dealing with patients who develop fistulas, one must keep in mind the gravity of this complication. A surgeon must always be on the look-out for its development and ensure a proper way of dealing with it, as it may lead to the loss of the patient.

The main ways to treat the digestive fistulas are medical, interventional radiology, endoscopy and surgery.

The medical treatment usually is a supportive therapy in order to correct the homeostasis of the body and to enhance the nutrition necessary for healing.

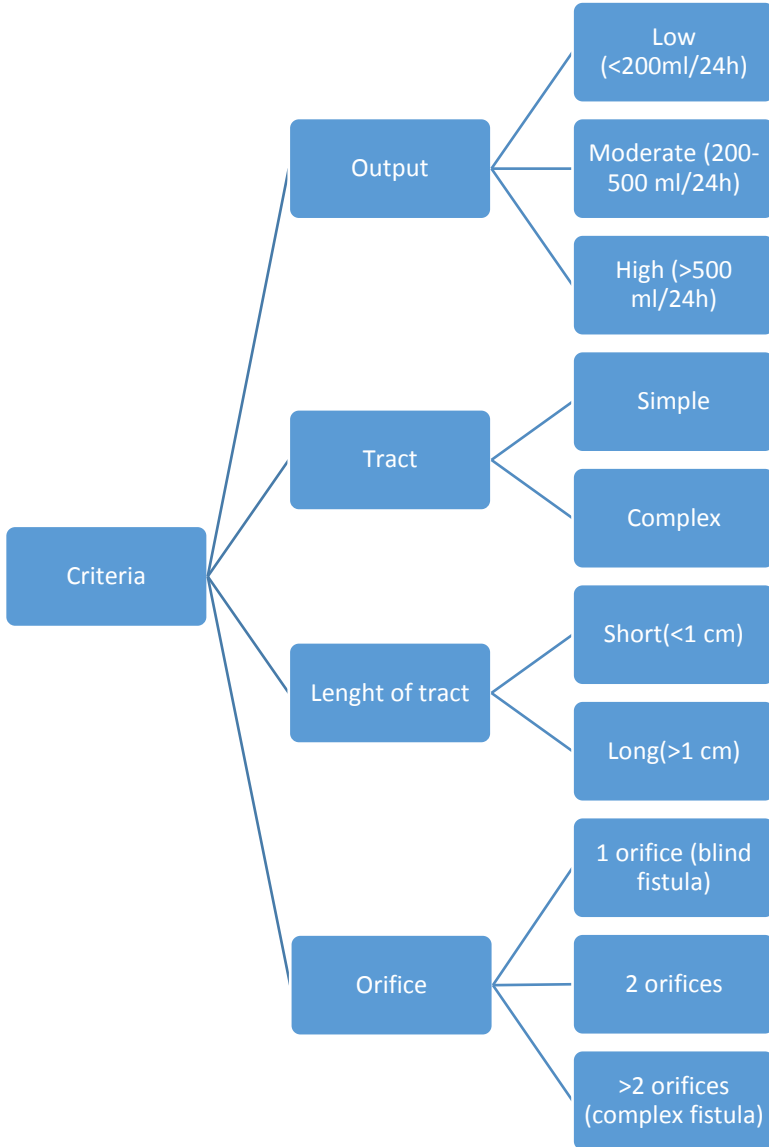


Figure 1. Criteria for digestive fistulas classification.

The interventional radiology could drain the intraabdominal fluid collection and insert drainage tubes or prosthesis (to keep open the lumen of some hollow organs).

Endoscopy seems to bring a new wave in the therapy of digestive fistulas along with the development of specialized stents, clips, suturing devices, glues and suction sponges.

Surgery remains the last treatment if all the others failed and also is reserved in the cases with no other solutions from the beginning (in situations that put the patient's life in danger - peritonitis, abscesses, etc.)

References

- [1] Falconi, M. and P. Pederzoli, *The relevance of gastrointestinal fistulae in clinical practice: a review*. Gut, 2001. 49(Suppl 4): p. iv2-iv10.
- [2] Edmunds, L. H., G. M. Williams, and C. E. Welch, *External Fistulas Arising From the Gastro-intestinal Tract*. Annals of Surgery, 1960. 152(3): p. 445-469.
- [3] Alvarez, C., D. W. McFadden, and H. A. Reber, *Complicated enterocutaneous fistulas: failure of octreotide to improve healing*. World J Surg, 2000. 24(5): p. 533-7; discussion 538.
- [4] Haffeejee, A. A., *Surgical management of high output enterocutaneous fistulae: a 24-year experience*. Curr Opin Clin Nutr Metab Care, 2004. 7(3): p. 309-16.
- [5] Makhdoom, Z. A., M. J. Komar, and C. D. Still, *Nutrition and enterocutaneous fistulas*. J Clin Gastroenterol, 2000. 31(3): p. 195-204.
- [6] Campos, A. C., et al., *A multivariate model to determine prognostic factors in gastrointestinal fistulas*. J Am Coll Surg, 1999. 188(5): p. 483-90.
- [7] Memon, A. S. and F. G. Siddiqui, *Causes and management of postoperative enterocutaneous fistulas*. J Coll Physicians Surg Pak, 2004. 14(1): p. 25-8.
- [8] Rots, W. I. and T. Mokoena, *Successful endoscopic closure of a benign gastrocolonic fistula using human fibrin sealant through gastroscopic approach: a case report and review of the literature*. Eur J Gastroenterol Hepatol, 2003. 15(12): p. 1351-6.
- [9] Rahbour, G., et al., *A meta-analysis of outcomes following use of somatostatin and its analogues for the management of enterocutaneous fistulas*. Ann Surg, 2012. 256(6): p. 946-54.

- [10] J. C., *Current Surgical Therapy. 7th Ed.* 2001, St. Louis: Mosby.
- [11] V., C., et al., *Fistulele gastrice postoperatorii asociate cu sepsis sever* Jurnalul Rom ân de Anestezie Terapie Intensivă, 2010. 17(1): p. 55-60.
- [12] Berry, S. M. and J. E. Fischer, *Classification and pathophysiology of enterocutaneous fistulas.* Surg Clin North Am, 1996. 76(5): p. 1009-18.
- [13] Fischer, J. E., *The pathophysiology of enterocutaneous fistulas.* World J Surg, 1983. 7(4): p. 446-50.
- [14] Chintapatla, S. and N. A. Scott, *Intestinal failure in complex gastrointestinal fistulae.* Nutrition, 2002. 18(11-12): p. 991-6.
- [15] Hyman, N., et al., *Anastomotic leaks after intestinal anastomosis: it's later than you think.* Ann Surg, 2007. 245(2): p. 254-8.
- [16] van Rooijen, S. J., et al., *Intraoperative modifiable risk factors of colorectal anastomotic leakage: Why surgeons and anesthesiologists should act together.* Int J Surg, 2016. 36(Pt A): p. 183-200.
- [17] Tsuei, B. J., et al., *The open peritoneal cavity: etiology correlates with the likelihood of fascial closure.* Am Surg, 2004. 70(7): p. 652-6.
- [18] Galanopoulos, M., et al., *A rectovaginal fistula after treatment with bevacizumab. A dangerous side effect needing emergency treatment.* Clinical Case Reports, 2016. 4(4): p. 449-450.
- [19] Chen, J., R. D. Smalligan, and S. Nadesan, *When a good call leads to a bad connection: colovesical fistula in colorectal cancer treated with bevacizumab.* Hosp Pract (1995), 2016. 44(3): p. 120-2.

